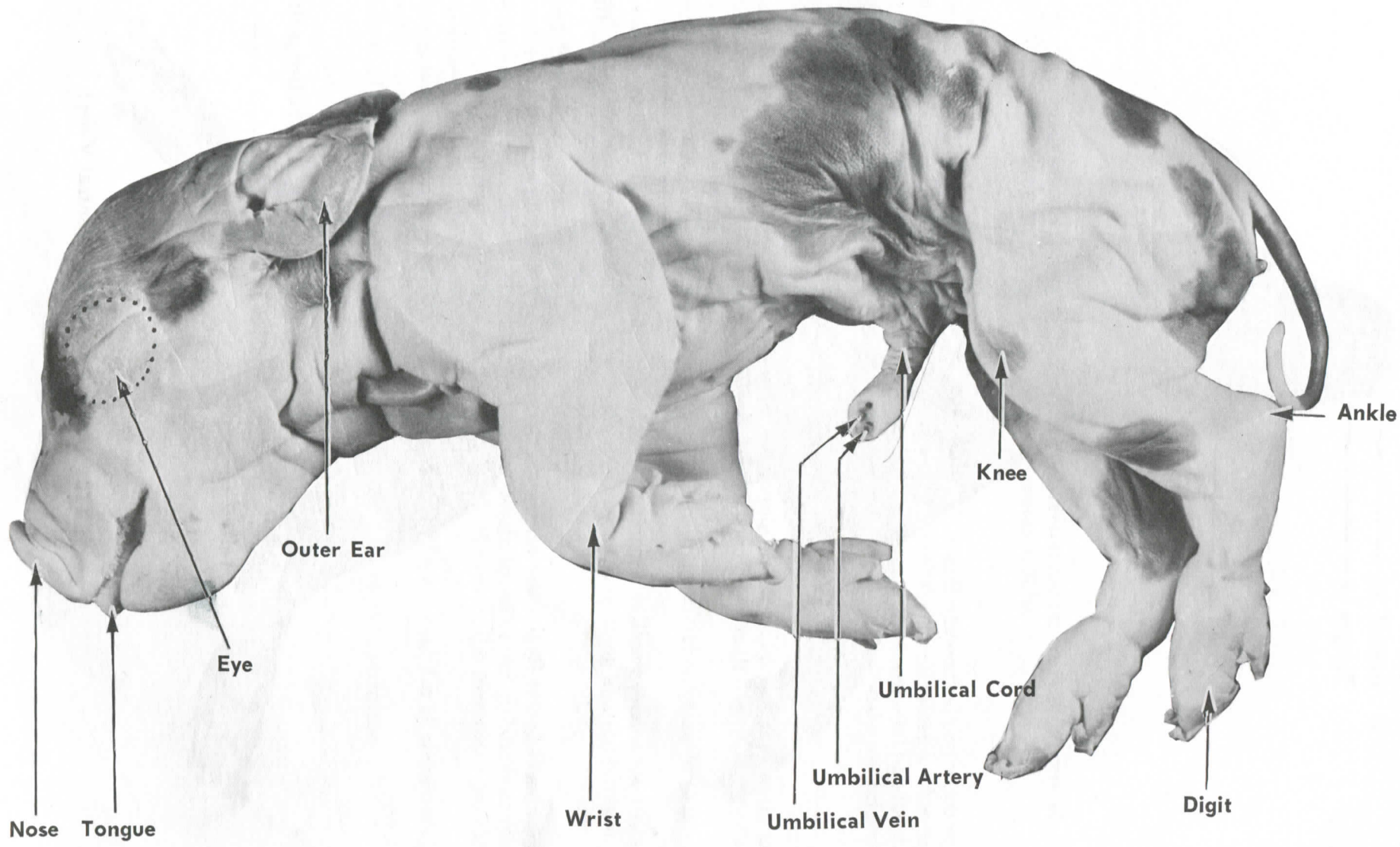


Head	Neck		Trunk		Tail
Cranial	Cervical	Thoracic	Lumbar	Sacral	Caudal



EXTERNAL STRUCTURES